

DEVELOPMENT OF MACULAR PSEUDOHOLES

A 36-Month Period of Follow-up

MONICA VARANO, MD,* CECILIA SCASSA, MD,*
NICOLETTA CAPALDO, MD,* MARTA SCIAMANNA, MD,*
VINCENZO PARISI, MD*†

Purpose: To assess the changes in visual acuity and macular sensitivity and the possible evolution into a full-thickness macular hole in patients with macular pseudoholes during a 3-year follow-up period.

Methods: Twenty-seven eyes (mean age, 61.0 ± 8.9 years) with macular pseudoholes were enrolled. They were compared with 16 eyes from 16 age-matched control eyes. In each eye with a macular pseudohole, we assessed the Snellen visual acuity and macular sensitivity by scanning laser ophthalmoscopic central ($1-2^\circ$ of the macula, SLO-CM) and paracentral (annular area from $2-7^\circ$ from the macula, SLO-PM) microperimetry at the time of diagnosis (baseline condition) and every 6 months for 3 years.

Results: Eyes with macular pseudoholes at baseline had a significant ($P < 0.05$) reduction in visual acuity, SLO-CM, and SLO-PM when compared with control eyes. After 12 months of follow-up, no changes in VA, SLO-CM, or SLO-PM were observed in eyes with macular pseudoholes with respect to the baseline values. After 36 months of follow-up, further significant ($P < 0.05$) decreases in visual acuity, SLO-CM, and SLO-PM were observed. One third of eyes with macular pseudoholes showed an evolution into a full-thickness macular hole. In these eyes, the lowest SLO-CM had been observed at the baseline condition.

Conclusion: This study suggests that in the 36-month follow-up period in eyes with macular pseudoholes, there is the possibility of a worsening trend, leading to the development of a full-thickness macular hole. A useful role of the functional assessment by SLO-CM and SLO-PM can be suggested for the clinical diagnosis and the follow-up of macular pseudoholes.

RETINA 22:435-442, 2002

Macular pseudoholes (MPHs) are well-demarcated, round or oval defect images occurring in a fibrocellular membrane overlying the foveal region.¹⁻⁴ Ho et al⁵ and Gass⁶ suggested that MPHs could be caused by centrifugal contraction of the

fenestrated membrane, with slight central movement of the underlying retina and steepening of the foveal margin, which create the appearance of a hole. Where this traction persists, it causes a progressive retinal thinning that can also evolve into a full-thickness hole.

The clinical diagnosis of MPH is based on slit-lamp examination with funduscopy lenses or on retinal fluorescein angiography, which allows us to assess the presence of retinal edema or hyperfluorescence caused by epiretinal contracted membranes.^{3,6,7} Nevertheless,

From *Fondazione per l'Oftalmologia G.B. Bietti, Rome; and †Cattedra di Clinica Oculistica, Università di Roma "Tor Vergata," Rome, Italy.

Reprint requests: Monica Varano, MD, Fondazione per l'Oftalmologia G.B. Bietti, Piazza Sassari 5, 00162 Rome, Italy; e-mail: md2180@mclink.it

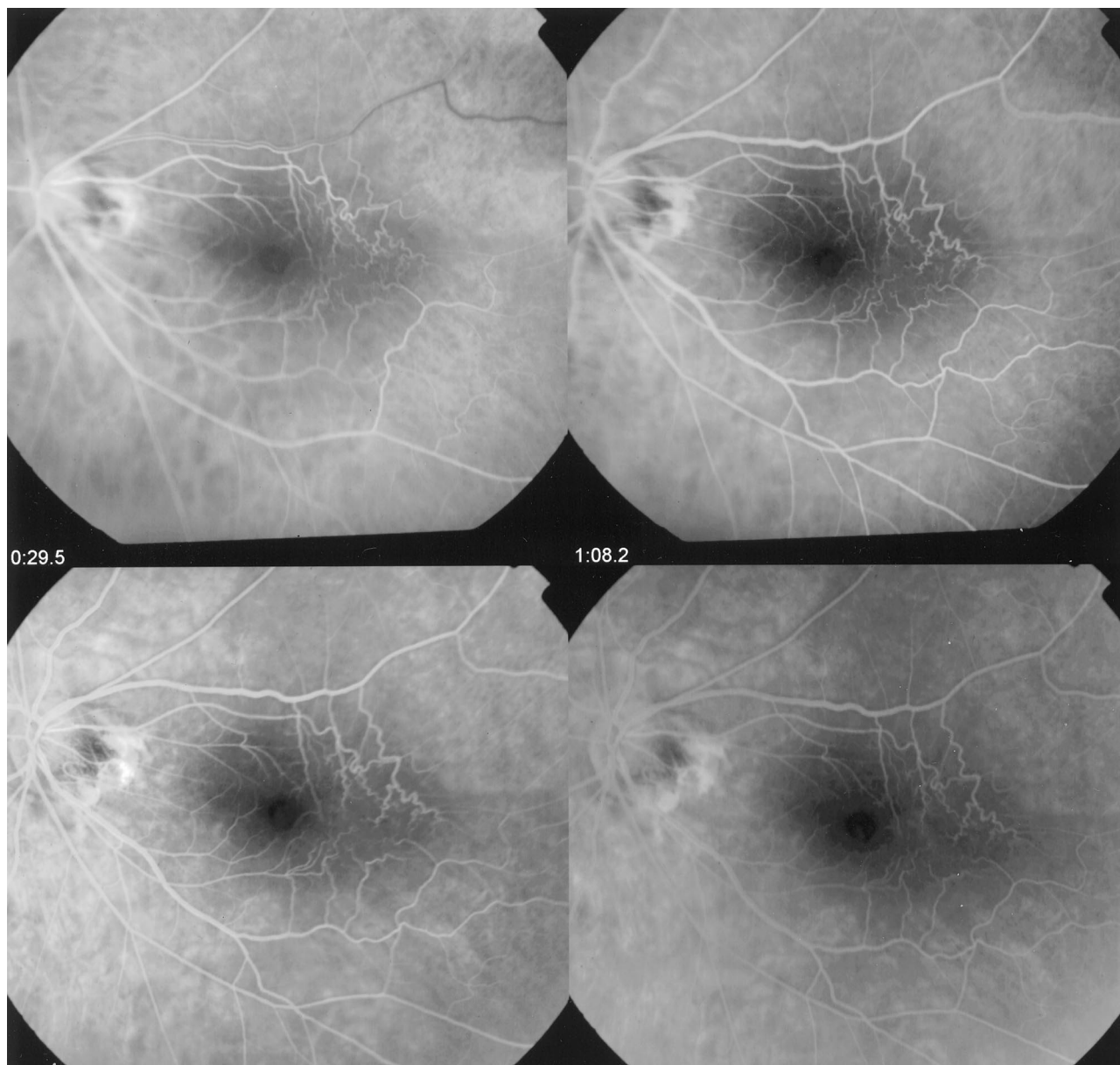


Fig. 1. Example of a fluorescein angiogram in a patient with a macular pseudohole. The fluorescein angiogram shows an early hyperfluorescence within the area of the pseudohole and an increased tortuosity or abnormal straightening of the perifoveal vessels.

fluorescein angiography is not able to differentiate this vitreoretinal entity from other similar syndromes, such as a full-thickness macular hole or lamellar hole.⁷

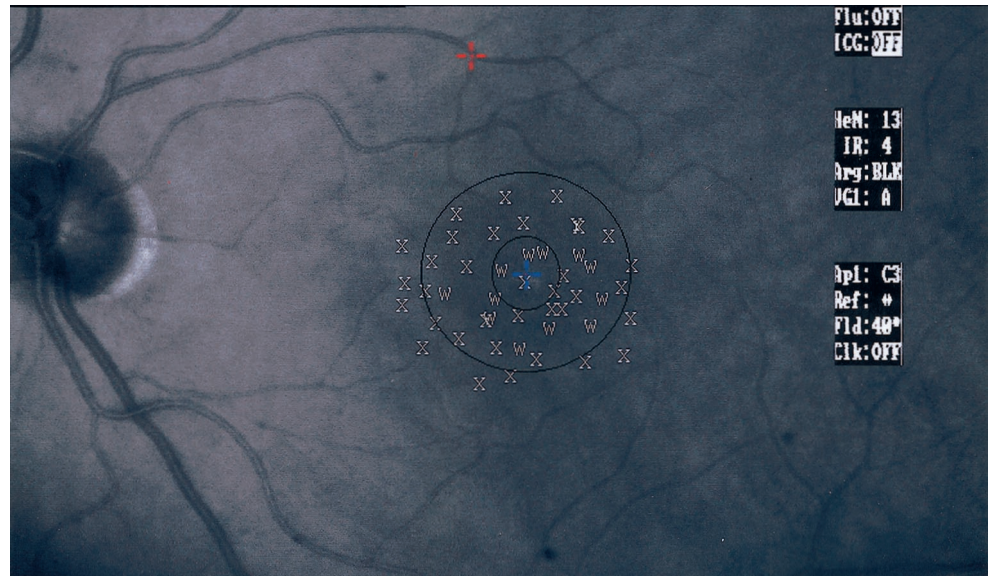
Another diagnostic tool in macular pathology is the scanning laser ophthalmoscope (SLO), which allows a morphologic study by providing high-definition images of the anatomic modifications occurring in MPH evolution⁸, and a functional evaluation of central retinal sensitivity by using SLO microperimetry.⁹⁻¹²

In particular, SLO microperimetry offers the advan-

tage of differentiating full-thickness macular holes from MPHs. A full-thickness macular hole always produces an absolute scotoma, whereas an MPH shows normal or low retinal sensitivity but not an absolute scotoma.^{4,9,12,13}

This study aims to assess changes in visual acuity and macular sensitivity by SLO microperimetry and the possible evolution into a full-thickness macular hole in patients with MPHs during a 3-year follow-up period.

Fig. 2. Example of scanning laser ophthalmoscope microperimetry in a healthy patient. The values of macular sensitivity are expressed as letters (from A corresponding to 0 decibels, to Z corresponding to 25 decibels) and the perimetric examination comprises 33×21 degrees of the macular area. Macular sensitivity is evaluated in central (first solid line around the fixation cross corresponding to $1-2^\circ$ of the macula) and paracentral microperimetry (second solid line corresponding to an annular area from $2-7^\circ$ central degrees).



Patients and Methods

Patients

Twenty-seven eyes from 27 patients (14 men and 13 women; mean age, 61.0 ± 8.9 years) with MPHs were enrolled in the study. The clinical diagnosis of MPH was based on the ophthalmoscopic presence of vitreous cortex remaining adherent to the retinal surface, determining tangential traction, and causing a demarcated round defect in the macular region.

The 27 eyes were compared with 16 eyes from 16 age-matched controls. For patients and controls, exclusion criteria included the presence of dense lens opacities, glaucoma, diabetic retinopathy, drusen and age-related macular disease, refractive error greater than ± 4 spherical diopters, and other diseases such as systemic hypertension, diabetes, and connective tissue diseases.

A common fluorescein angiographic characteristic associated with MPHs (75% of our cases) is early hyperfluorescence within the area of the pseudohole. This hyperfluorescence coincides with choroidal filling and appears to be a form of transmission defect rather than a blocking of surrounding choroidal fluorescence by the epiretinal membrane. This central hyperfluorescence may result in misdiagnosis of the MPH as a full-thickness macular hole. No fluorescence was seen in 25% of the eyes with an MPH. In almost all the cases of MPH, increased tortuosity or abnormal straightening of the perifoveal vessels was present (Figure 1).

Examination

In each patient, we assessed visual acuity and macular sensitivity at the time of diagnosis (baseline condition) and every 6 months for 36 months.

Visual acuity was measured using a standard Snellen visual acuity chart, with a presentation of 10 lines ranging from 20/200 to 20/20. Patients were seated 3 meters from the illuminated chart and tested monocularly with their best refractive correction.

Macular sensitivity was assessed by SLO microperimetry (Rodentock, Dusseldorf, Germany), which allows for an exact point-to-point correspondence between fundus image and perimetry results. A helium-neon laser beam (633 nm) and an infrared diode laser (780 nm) were simultaneously projected into the retina and detected through a selection of confocal apertures. The infrared laser, which is invisible to the patient, was used for retinal imaging, allowing for a satisfactory exploration when lens or vitreous opacities are present. Stimulus generation for psychophysical testing is obtained by using a helium-neon laser beam. This laser, used for the generation of the background and stimulus illumination, is modulated by an acousto-optic modulator.^{10,11}

The central fixation target is a cross directly projected onto the foveal area and visualized on the monitor display. The search for liminal value, by static manual perimetry, is performed by testing 25 to 30 points in the macular area. The test starts from a supraliminal stimulus. The area of perimetric examination comprises 33×21 degrees or 16.5×10.5 degrees. The acousto-optic modulator rapidly changes the intensity of the scanned laser beam in response to

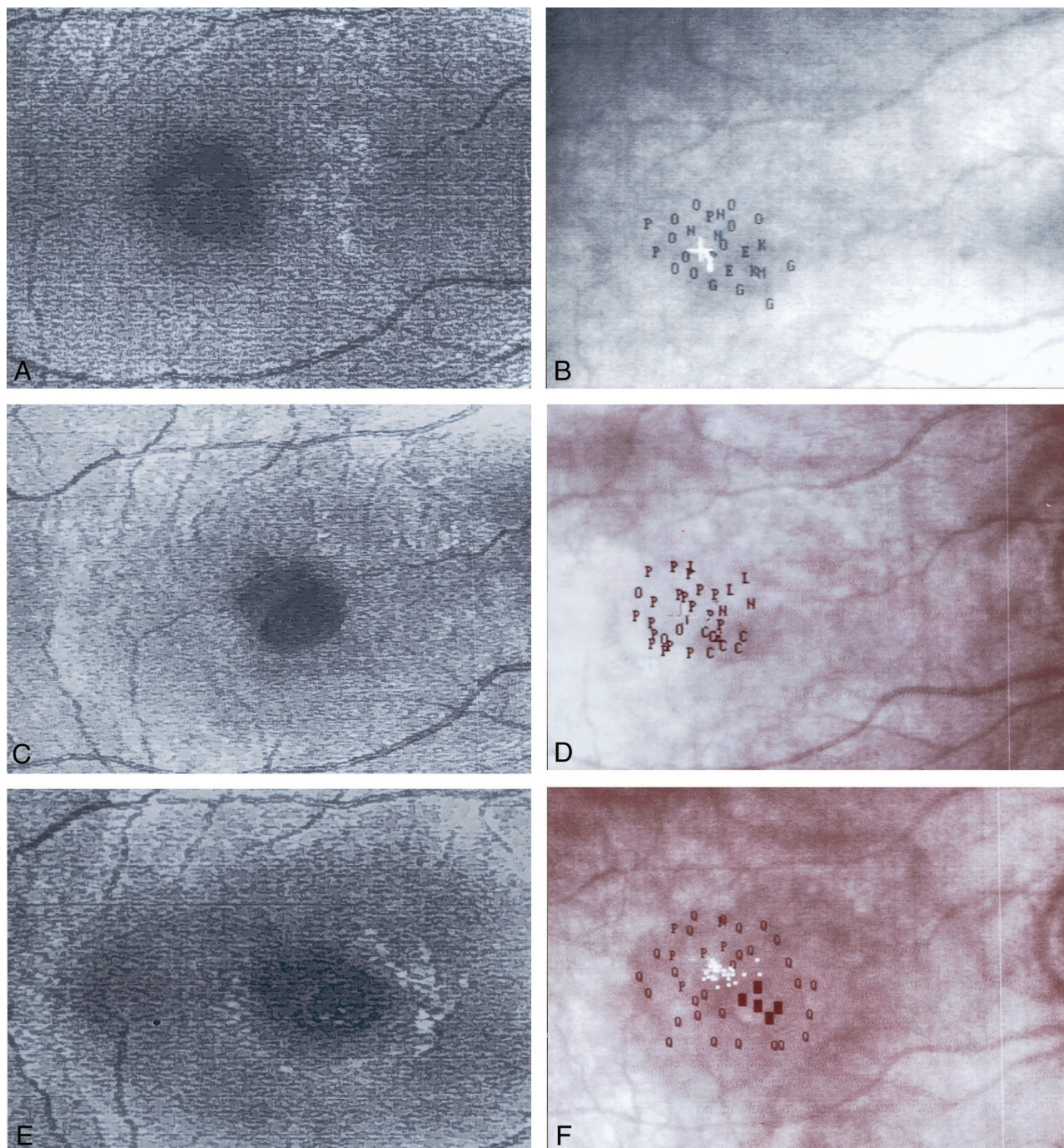


Fig. 3. Example of scanning laser ophthalmoscope (SLO) ophthalmoscopy (A, C, E) and SLO microperimetry (B, D, F) in baseline conditions (A, B), after 12 months of follow-up (C, D), and after 18 months of follow-up (E, F) in a patient affected by macular pseudohole that evolved into a full-thickness macular hole. The baseline SLO ophthalmoscopy (A) shows a typical pseudohole aspect of the central area and the presence of vitreous cortex adherent to the retinal surface. The baseline microperimetry (B) evaluated in central (first solid line corresponding to 1–2° of the macula) and paracentral (annular area from 2–7°) shows a decrease in macular sensitivity compared with controls. In this patient after 12 months, SLO ophthalmoscopy (C) shows a central retinal thinning, whereas retinal sensitivity (D) shows a decrease in sensitivity in this small area. In the same patient after 18 months of follow-up, SLO ophthalmoscopy (E) shows a full-thickness macular hole. SLO microperimetry (F) shows the appearance of an absolute scotoma in the central sensitivity area whereas the paracentral microperimetry seems to be unchanged.

Table 1. Clinical Characteristics of Eyes With Macular Pseudoholes in Baseline Condition and Age-Matched Control Eyes

Group	No. of Eyes	Sex, M/F	Age, yr	Visual Acuity	Central Microperimetry, dB	Paracentral Microperimetry, dB
Controls	16	9/7	62.8 ± 8.55	19.6 ± 0.8/20	19.3 ± 1.08	18.9 ± 1.34
Macular pseudohole	27	14/13	61.0 ± 8.89	14.0 ± 05.6/20*	14.4 ± 2.2*	14.5 ± 2.1*

Values are expressed as mean ± standard deviation.

* $P < 0.05$, analysis of variance with respect to control eyes.

electronic signals from the graphics generator in the SLO computer. The stimuli are observed by the patient, while the observers see the images of the stimuli directly on the patient's retina. Stimuli of increasing luminance are presented for each point. Microperimetry is performed with a differently sized point stimulus, ranging from Goldmann I (0.25 mm²) to Goldmann IV.^{10,13} Those stimuli that have not been seen are then removed until minimal luminance is achieved. Stimuli with different decibel values are presented by letters (from A corresponding to 0 dB, to Z corresponding to 25 dB). Missed stimuli, represented with the corresponding letter, are also stored and visualized with a small, dark square. The digital fundus image is frozen and saved on the hard disk after the test of the macular area is completed. The SLO provides a 32 × 22 degree image of the fundus with a maximal resolution of 4 minutes of visual arc (20 nm) for measurement and positioning of targets. The SLO allows the detection of early functional reduction of retinal sensitivity and the eventual relocation of the fixation point in MPH and macular hole. The examiner is able to locate the real fixation area to note whether it was inside the fovea or on the upper, lower, temporal, or nasal area of the macula.

We studied macular sensitivity, testing the mean value expressed in dB of six to eight retinal points of the central 1° to 2° of the macula (central micrope-

rimetry) and the mean value of 15 to 20 retinal points dislocated in an annular area from 2° to 7° central degrees (paracentral microperimetry) (Figures 2 and 3).

Statistics

The differences observed in eyes with MPH in the baseline condition with respect to control eyes and the differences in eyes with MPH after 6, 12, 18, 24, 30, and 36 months with respect to the baseline condition, have been evaluated by one-way analysis of variance. The correlation between visual acuity and microperimetry (central and paracentral evaluation) was evaluated by linear regression (Pearson's test). In both statistical analyses, a P value less than 0.05 was considered significant.

Results

Baseline Condition

In the baseline condition, eyes with MPH showed a significant ($P < 0.05$) reduction in visual acuity and in macular sensitivity (central and paracentral) when compared with control eyes. The mean data are expressed in Tables 1 and 2. In eyes with MPH, visual acuity was significantly ($P < 0.05$) correlated to the values of central and paracentral macular sensitivity (Table 3).

Table 2. Visual Acuity and Microperimetry Observed in Eyes With Macular Pseudoholes

Time	Visual Acuity	Central Microperimetry, dB	Paracentral Microperimetry, dB
Baseline	15.1 ± 4.8/20	14.4 ± 2.2	14.7 ± 2.0
6 mo	14.0 ± 5.6/20*	14.4 ± 2.2*	14.5 ± 2.1*
12 mo	13.1 ± 6.0/20*	14.1 ± 2.2*	14.2 ± 2.0*
18 mo	11.5 ± 5.8/20†	12.5 ± 3.8†	13.2 ± 2.0†
24 mo	10.9 ± 5.6/20†	11.0 ± 4.8†	12.9 ± 2.3†
30 mo	10.4 ± 5.8/20†	8.6 ± 6.4†	12.4 ± 2.3†
36 mo	9.5 ± 5.4/20†	8.4 ± 6.3†	12.0 ± 2.5†

Values are expressed as mean ± standard deviation.

* Not significant ($P > 0.05$).

† $P < 0.05$, analysis of variance with respect to baseline condition.

Table 3. Linear Regression and Correlation (Pearson's Test) Between Central and Paracentral Microperimetry at the Baseline Evaluation and Visual Acuity During the 36-Month Follow-Up Period Observed in Eyes With Macular Pseudoholes

Visual Acuity	Central Microperimetry	Paracentral Microperimetry
Baseline	r = 0.663 t = 4.164 P = 0.0004	r = 0.548 t = 3.076 P = 0.005
6 mo	r = 0.668 t = 4.449 P = 0.0002	r = 0.542 t = 3.030 P = 0.006
12 mo	r = 0.654 t = 4.061 P = 0.0005	r = 0.369 t = 1.863 P = 0.075
18 mo	r = 0.545 t = 3.053 P = 0.005	r = 0.300 t = 1.479 P = 0.153
24 mo	r = 0.530 t = 2.938 P = 0.007	r = 0.228 t = 1.102 P = 0.282
30 mo	r = 0.421 t = 2.181 P = 0.040	r = 0.098 t = 0.464 P = 0.646
36 mo	r = 0.467 t = 2.481 P = 0.021	r = 0.139 t = 0.659 P = 0.516

Thirty-Six Month Follow-Up

Examples of SLO ophthalmoscopy and microperimetry are shown in Figure 3.

The mean data of visual acuity and central and paracentral macular sensitivity observed after 6, 12, 18, 24, 30, and 36 months in eyes with MPH are reported in Table 2. In eyes with MPH, during the 36-month follow-up period, we observed changes in visual acuity and macular sensitivity, with respect to

the baseline condition. After 6 and 12 months of follow-up, the visual acuity and microperimetric (central or paracentral) values were unchanged with respect to those observed in the baseline condition. After 18 months of follow-up, we observed a significant ($P < 0.05$) reduction in visual acuity and central and paracentral macular sensitivity. After 24, 30, and 36 months of follow-up, we observed a further significant ($P < 0.05$) reduction in visual acuity and central and macular sensitivity, indicating a worsening trend of functional parameters. Central and paracentral microperimetry observed in the baseline condition was significantly ($P < 0.05$) correlated to the values of visual acuity observed at 6 and 12 months. At 18, 24, 30, and 36 months of follow-up, a significant ($P < 0.05$) correlation between visual acuity and central baseline microperimetric values has been observed, whereas no correlations were found between visual acuity and paracentral baseline microperimetry. The correlation between baseline central and paracentral microperimetry and visual acuity is shown in Table 3.

At 36 months of follow-up, we observed that 15 eyes (55.5%) with MPH had no changes in visual acuity or macular ophthalmoscopic aspect with respect to the baseline condition. Twelve patients (44.5%) with MPH showed a decrease in visual acuity and changes in the ophthalmoscopic aspect of the macular region. Nine of these (33.3%) had an evolution into a full-thickness macular hole at the ophthalmoscopic examination. Based on the follow-up characteristics, with a retrospective analysis, we divided all eyes with MPH into three groups: Group A included eyes in which the visual acuity and macular ophthalmoscopic aspect were unchanged. Group B included eyes in which a decrease in visual acuity and a modification of the macular ophthalmoscopic aspect

Table 4. Clinical Characteristics of Eyes With Macular Pseudoholes (in Baseline Conditions and After 36-Months of Follow-Up) and Age-Matched Controls

Patient Group	Sex		Age, yr (Baseline)	Visual Acuity		Central Microperimetry, dB		Paracentral Microperimetry, dB	
	N	M/F		Baseline	Follow-up	Baseline	Follow-up	Baseline	Follow-up
Controls	16	9/7	62.8 ± 8.5	19.6 ± 0.8/20	—	19.3 ± 1.08	—	18.9 ± 1.34	—
A	15	10/5	61.47 ± 11.0	15.4 ± 5.6/20*	15.4 ± 5.6/20	14.67 ± 2.28*	14.32 ± 2.32	14.87 ± 2.11*	14.22 ± 2.08*
B	3	2/1	68.0 ± 4.43	18.0 ± 2.0/20*	13.2 ± 2.2/20‡	15.33 ± 0.29*	12.28 ± 0.56‡	15.67 ± 0.29*	14.36 ± 0.32‡
C	9	6/3	63.56 ± 5.50	14.4 ± 5.8/20*	8.4 ± 3.4/20‡	9.22 ± 3.95†*	0.26 ± 0.22‡	13.72 ± 1.66*	10.54 ± 1.48‡

The eyes with macular pseudoholes were divided into three groups by a retrospective evaluation based on macular ophthalmoscopic changes after 36 months of follow-up. In group A, unmodified visual acuity and macular ophthalmoscopic aspect was observed; in group B, a decrease in visual acuity and a modification of macular ophthalmoscopic aspect was observed, such as a tangential traction caused by the vitreous cortex producing a demarcated round defect in the macular region; in group C, a great reduction of visual acuity and the ophthalmoscopic evaluation revealed a development into full-thickness macular hole was found.

Values are expressed as mean ± standard deviation.

* $P < 0.05$, analysis of variance with respect to control eyes.

† $P < 0.05$, analysis of variance with respect to groups A and B.

‡ $P < 0.05$, analysis of variance with respect to the baseline condition in each group.

were observed, such as a tangential traction caused by the vitreous cortex producing a demarcated round defect in the macular region. Group C included eyes that showed the greatest reduction in visual acuity and a development into a full-thickness macular hole.

In group C, we found the concomitant presence of an absolute scotoma at the central microperimetry. With the retrospective analysis presented in Table 4, we observed that eyes in group C showed the lowest values of central microperimetry with respect to control eyes and with respect to groups A and B ($P < 0.05$), at the baseline condition. None of the patients in group C had baseline central microperimetry values that overlapped with those of patients in groups A and B. No significant differences ($P > 0.05$) in baseline visual acuity or paracentral microperimetry were found in eyes in group C with respect to controls and with respect to other patients with MPH.

Discussion

The aim of our study was to assess changes in visual acuity and macular sensitivity and the possible evolution into a full-thickness macular hole in eyes with an MPH during a 36-month follow-up period.

At 12 months of follow-up, we observed no changes in visual acuity and central or paracentral microperimetry in eyes with MPH. Our data confirm the study by Greven et al,² in which stable visual acuity in eyes with MPH is described after the same follow-up period. In addition, Greven et al² observed ophthalmoscopic changes in 74% of the eyes enrolled.

In the literature, there are no data reported from eyes with MPH with a follow-up period longer than 1 year. Our results, regarding the 12- to 36-month follow-up period in patients with MPH, could represent a new finding.

In the 18- to 36-month period of follow-up, a significant reduction in visual acuity and macular (central and paracentral) sensitivity was found, and, in particular, we observed that 9 of 27 cases of MPH (33.3%) developed into full-thickness macular holes. The development into full-thickness macular holes could be explained by the characteristics of patients with MPH at the baseline condition. These can be derived from the retrospective analysis of the ophthalmoscopic changes observed after 36 months of follow-up. With this analysis, we found that eyes with MPH showed three different modalities of evolution: eyes maintaining the same values of visual acuity and retinal sensitivity (group A), eyes showing a worsening trend of all tested parameters (group B), and eyes in which there was a great reduction of visual acuity and an absolute scotoma (group C). When we observed the baseline values of patients in these groups, we found

that there were no differences in visual acuity and paracentral microperimetry among groups A, B, and C, whereas the lowest central microperimetry was observed in patients in group C with respect to patients in groups A and B.

Our results suggest that there is a different evolution of MPH, in relation to the baseline central or paracentral microperimetric values; the patients who develop full-thickness macular holes are the same patients who showed the lowest baseline central microperimetry.

When the evolution of MPH into full-thickness macular hole was observed in patients in group C, SLO microperimetry showed the appearance of an absolute scotoma in the central sensitivity area, surrounded by an area with slight reduction of sensitivity related to the time of onset of the macular hole. SLO microperimetry also detected a modification of the fixation point, which appears to be dislocated supratemporally in right eyes and supranasally in left eyes. These observations confirm those of Guez et al⁸ and Acosta et al,¹⁴ who, using SLO microperimetry, evidenced a new preferred retinal locus at the upper edge of a macular lesion, corresponding to the lower visual field.

This study suggests the diagnostic and prognostic importance of SLO microperimetry in patients with MPH. SLO provides a well-defined ophthalmoscopic evaluation and the possibility of carrying out a functional study by using microperimetry.

In the follow-up of eyes with MPH, SLO microperimetry shows a reduction of macular sensitivity along with a worsening of visual acuity, which could be ascribed to the centrifugal tangential traction exercised from the cortex at the retinal surface, giving rise to an MPH.^{5,6} These vitreoretinal interface changes can be objectively evaluated by SLO ophthalmoscopy, which allows us to detect the morphology of MPH, showing the foveal thinning caused by the tractional effect of tangential forces.¹⁵

Our results suggest that in eyes with MPH during the 36-month follow-up period, there is the possibility of a worsening trend leading to the development of a full-thickness macular hole. A useful role of the functional assessment of central macular sensitivity, performed by SLO microperimetry, can be suggested for the clinical diagnosis and follow-up of MPH.

Key words: macular pseudohole, macular hole, scanning laser ophthalmoscope, scanning laser ophthalmoscopic microperimetry.

References

1. Massin P, Paques M, Masri H, et al. Visual outcome of surgery for epiretinal membranes with macular pseudoholes. *Ophthalmology* 1999;106:580–585.

2. Greven C, Slusher MM, Czyz CN. The natural history of macular pseudoholes. *Am J Ophthalmol* 1998;125:360–366.
3. Fish RH, Anand R, Izbrand DJ. Macular pseudoholes: clinical features and accuracy of diagnosis. *Ophthalmology* 1992;99:1665–1670.
4. Martinez J, Smiddy WE, Kim J, Gass JD. Differentiating macular holes from macular pseudoholes. *Am J Ophthalmol* 1994;117:762–767.
5. Ho AC, Guyer DR, Fine SL. Macular hole. *Surv Ophthalmol* 1998;42:393–416.
6. Gass DJM. Reappraisal of biomicroscopic classification of stages of development of a macular hole. *Am J Ophthalmol* 1995;119:752–759.
7. Klein BR, Hiner CJ, Glaser BM, et al. Fundus photographic and fluorescein angiographic characteristics of pseudoholes of the macula in eyes with epiretinal membranes. *Ophthalmology* 1995;102:768–774.
8. Guez JE, Le Gargasson JF, Massin P, et al. Functional assessment of macular hole surgery by scanning laser ophthalmoscope. *Ophthalmology* 1998;105:694–699.
9. Kakehashi A, Ishiko S, Konno S, et al. Differential diagnosis of macular breaks by microperimetry using the scanning laser ophthalmoscope. *Jpn J Ophthalmol* 1996;40:116–122.
10. Varano M, Scassa C. Scanning laser ophthalmoscope microperimetry. *Semin Ophthalmol* 1998;13:203–209.
11. Rohrschneider K, Fendrich T, Becker M, et al. Static fundus perimetry using the scanning laser ophthalmoscope with an automated threshold strategy. *Graefes Arch Clin Exp Ophthalmol* 1995;233:743–749.
12. Sjaarda RN, Frank DA, Glaser BM, et al. Assessment of vision in idiopathic macular holes with macular microperimetry using the scanning laser ophthalmoscope. *Ophthalmology* 1993;100:1513–1518.
13. Tsujikawa M, Ohji M, Fujikado T, et al. Differentiating full thickness macular holes from impending macular holes and macular pseudoholes. *Br J Ophthalmol* 1997;81:117–122.
14. Acosta F, Lashkari K, Reunauld X, et al. Characterization of functional changes in macular holes and cysts. *Ophthalmology* 1991;98:1820–1823.
15. Varano M, Billi B, Scassa C, et al. Scanning laser ophthalmoscopy in the early diagnosis of vitreo interface syndrome. *Retina* 1997;17:300–305.