

OPA1 Mutations Associated with Dominant Optic Atrophy Influence Optic Nerve Head Size

Piero Barboni, MD,^{1,2} Michele Carbonelli, MD,¹ Giacomo Savini, MD,³ Beatrice Foscarini, MD,² Vincenzo Parisi, MD,³ Maria L. Valentino, MD,² Arturo Carta, MD,⁴ Annamaria De Negri, MD,⁵ Federico Sadun, MD,⁶ Massimo Zeviani, MD, PhD,⁷ Alfredo A. Sadun, MD, PhD,⁸ Simone Schimpf, PhD,⁹ Bernd Wissinger, PhD,⁹ Valerio Carelli, MD, PhD²

Purpose: To analyze the influence of *OPA1* gene mutations on the optic nerve head (ONH) morphology in patients with dominant optic atrophy (DOA).

Design: Cross-sectional study.

Participants: Twenty-eight patients with DOA from 11 pedigrees, which were positive for the presence of *OPA1* gene mutations, and 56 age-matched control subjects, were enrolled.

Methods: The ONH of DOA patients was studied by optical coherence tomography and compared with an age-matched control group of 56 individuals.

Main Outcome Measures: ONH area, and vertical and horizontal diameters.

Results: The ONH analysis of DOA patients showed a significantly smaller optic disc area ($P < 0.0001$), vertical ($P = 0.018$), and horizontal ($P < 0.0001$) disc diameters, compared with controls. Stratification of the results for the single *OPA1* mutation revealed normal ONH area with 2 mutations, whereas the only missense mutation linked to a “DOA plus” phenotype had the smallest ONH measurements.

Conclusions: The DOA patients carrying *OPA1* gene mutations present, as a group, a significantly smaller ONH compared with the range of size observed in a control population; this feature may be mutation specific. This observation suggests that *OPA1* is involved in shaping the anatomical conformation of the ONH in patients with DOA. The relevance of *OPA1* in regulating apoptosis and modeling the eye development has been recently shown by others. Thus, mutations in the *OPA1* gene may determine the previously unrecognized feature of a smaller optic disc size and this in turn may have relevance for DOA pathogenesis. Furthermore, *OPA1* gene polymorphic variants may contribute to the normal variability of ONH size in the general population.

Financial Disclosure(s): The authors have no proprietary or commercial interest in any of the materials discussed in this article. *Ophthalmology* 2010;117:1547–1553 © 2010 by the American Academy of Ophthalmology.

Dominant optic atrophy (DOA), initially described by Kjer,¹ is a degenerative disorder that affects retinal ganglion cells. It is characterized by a slowly progressive bilateral visual loss that starts in childhood and ultimately leads to optic atrophy.² Clinical examination demonstrates temporal or diffuse pallor of the optic disc, cecentral scotomas, impairments of color vision and optic disc excavation. Disease progression may be quite variable even within the same family, ranging from mild cases with visual acuity that stabilizes in adolescence, to slowly but relentlessly progressive cases, to cases with sudden, steplike decreases in visual acuity. This variability of clinical expression is reflected by the different extent of optic atrophy. Notwithstanding this variability, DOA is characterized by the early and preferential involvement of the small fibers in the papillomacular bundle.^{2,3} This is also seen in Leber's hereditary optic neuropathy (LHON) and is a hallmark of mitochondrial optic neuropathies.⁴

Most DOA cases have been associated with mutations in the *OPA1* gene, which encodes a dynamin-related GTPase targeted to mitochondria.^{5,6} The mutation spectrum include missense, nonsense, deletion/insertion, and splicing mutations that are distributed throughout the

gene (available: <http://lbbma.univ-angers.fr/eOPA1/> accessed September 28, 2009).⁷ The large majority of *OPA1* mutations are predicted to generate a truncated protein, most likely inducing haploinsufficiency, as the pathogenic mechanism underlying DOA.⁸ However, a few missense mutations affecting the GTPase domain have been recently associated with a syndromic form of optic atrophy named “DOA plus.” These patients suffer central and peripheral nerve system pathology as well as mitochondrial myopathy with accumulation of mitochondrial DNA multiple deletions, and a dominant negative effect has been postulated in these cases.^{9,10} A number of asymptomatic carriers of *OPA1* mutations have been identified within families, suggesting incomplete penetrance.¹¹ The *OPA1* protein localizes to the mitochondrial inner membrane, facing the intermembrane space, and is involved in multiple functions. A key role played by *OPA1* protein concerns fusion of mitochondria and mitochondrial network dynamics.¹² Furthermore, *OPA1* is also involved in oxidative phosphorylation (OXPHOS) and membrane potential maintenance,^{8,13–15} as well as cristae organization and control of apoptosis through the compartmentalization of cytochrome c.^{13,16,17}

Optic nerve head (ONH) size and conformation varies in humans.¹⁸ The ONH size has been studied in different ethnic groups and was linked to the predisposition for some ophthalmologic disorders. In fact, small optic disc size is a well-defined risk factor in nonarteritic ischemic optic neuropathy (NAION), as well as ONH drusen and glaucoma.^{19–22} We have recently shown that large ONH size may be protective in LHON patients, contributing to the reduced penetrance and favoring a better visual prognosis in affected individuals.²³

The current study sought to investigate the ONH anatomic size in DOA patients carrying *OPA1* gene mutations.

Subjects and Methods

Subjects

All DOA patients with a molecularly confirmed diagnosis of *OPA1* mutations who were referred to the Department of Neurological Sciences at the University of Bologna between 2002 and 2006 were invited to participate in this study. Between September and December 2006, 28 DOA patients from 11 unrelated pedigrees of European ancestry were recruited and examined by optical coherence tomography (OCT) imaging in both eyes. Exclusion criteria were the presence in 1 or both eyes of any retinal pathology and/or optic nerve disease other than DOA, and spherical and/or cylindrical refractive errors >5 and >2 diopters, respectively.

The control group ($n = 56$) was composed of volunteers recruited during routine refractive screening without evidence of either optic disc or retinal disease. All subjects underwent a comprehensive ophthalmologic examination, including best-corrected visual acuity measurement, slit-lamp biomicroscopy, intraocular pressure measurement, indirect ophthalmoscopy, and ONH photography. All participants gave their informed consent according to the Declaration of Helsinki; the study was approved by the internal review board of the Department of Neurological Sciences at the University of Bologna.

Instrumentation and Procedures

All measurements were obtained by a commercially available optical coherence tomographer (Stratus OCT, software version 4.0.1; Carl Zeiss Ophthalmic System Inc., Humphrey Division, Dublin, CA), as previously reported.²³ Optic nerve head analysis was performed with the Fast Optic Disc acquisition protocol. Six radial scans in a spoke like pattern are centered on the ONH and with each radial scan spaced 30° from one to another. Each radial scan included 128 measuring points. The machine automatically defined the edge of the optic disc as the end of the retinal pigment epithelium (RPE)/choriocapillaris and used smoothing with fit to circle to fill the gaps between scans.

The examination was performed under mydriasis by an experienced operator (PB) who was masked regarding the clinical status of each subject. At the beginning of the examination, the OCT lenses were adjusted for the patient's refractive error. Polarization was optimized to maximize the reflective signal and we sought the best centration of the scan with respect to the optic disc. Internal fixation was used whenever possible; patients with low central vision were asked to look laterally during the scan acquisition until the image of the optic disc appeared on the screen of the operator. When the fellow eye allowed it, external fixation was adopted.

As regards ONH analysis, the automatically defined ONH boundaries were manually repositioned if the RPE edges were not correctly identified by the software, so that the resulting ONH

profile did not fit with that observed by fundus photographs. In the event of peripapillary atrophy of the RPE, the optic disc edge was no longer identified on the basis of the RPE edge, but on the basis of the neuroretinal rim, as seen on the fundus photograph. Manual correction was carried out in 26 out of 28 DOA patients (92.8%) and in 45 out of 56 control subjects (80.3%).

Sequencing of the *OPA1* Gene

For *OPA1* gene analysis, genomic DNA was amplified by polymerase chain reaction (PCR) with specific primers designed to amplify all exons and flanking intronic regions as previously described.²⁴ The PCR reactions were carried out in 50 μ L volume with 50 to 100 ng genomic DNA, 10 mmol/L Tris-HCl pH 8.9, 50 mmol/L KCl, 1.5–3 mmol/L $MgCl_2$, and 200 μ mol/L of each dNTP, 10 pmol of primers, and 1 U AmpliTaq polymerase (Applied Biosystems, Weiterstadt, Germany). The PCR products were purified by ExoSAP treatment (USB, Staufien, Germany) and sequenced employing BigDye Terminator chemistry (Applied Biosystems). Total RNA was isolated from whole blood using the PAXgene Blood RNA system (Quiagen, Hilden, Germany). Single-stranded cDNA was synthesized applying the SuperScript First-Strand Synthesis System (Invitrogen, Carlsbad, CA) and overlapping fragments of the *OPA1* cDNA were amplified by PCR before direct DNA sequencing, as described previously.²⁵

Statistical Analysis

For statistical purposes, only 1 eye, randomly chosen, was considered for each DOA patient and control subject. All statistical analyses were performed with SPSS 12.0 (SPSS, Inc., Chicago, IL). Comparisons of mean values of OCT measurements, such as optic disc area and vertical and horizontal disc diameters between patients and the control group were performed by means of the unpaired *t*-test for parametric data and Mann-Whitney *U* test for nonparametric data to calculate the 2-tailed *P* value. $P < 0.05$ was accepted as significant in all analyses.

Results

For this study, we collected 28 DOA patients from 11 DOA pedigrees that segregate a pathogenic mutation in the *OPA1* gene (Tables 1 and 2). The control group consisted of 56 age-matched subjects. Demographic data (mean age and gender) of patients and controls are provided in Table 1. No patients were excluded because of these criteria. The mean age was not statistically different between these 2 groups.

Table 2 shows the *OPA1* mutations in the 11 pedigrees studied and the results of the OCT measurements stratified for the *OPA1* defect, having pooled the patients from different pedigrees with the same mutation. Most mutations are well-established *OPA1* patho-

Table 1. Demographic Characteristics of the Study Groups

	Dominant Optic Atrophy Patients (n = 28)	Control Groups (n = 56)
Subjects age (yrs)		
Mean (SD)	36.8 (20.5)	33.8 (9.3)
Range (median)	7–78 (38)	10–49 (35)
Male/female	16/12	31/25

SD = standard deviation.

Table 2. Genetic, Clinical, and Topographic Optic Nerve Head Measurements in Dominant Optic Atrophy Patients

Pedigree	No. Pedigree	No. Affected Patients	OPA1 Mutations	OPA1 Exon	Age		BCVA	Disc Area (mm ²)		Vertical Disc Diameter (mm)		Horizontal Disc Diameter (mm)	
					Mean (SD)	Mean (SD)		Mean (SD)	P	Mean (SD)	P	Mean (SD)	P
1,2	2	7	c.984+3A>T, splice defect	9	50 (24.9)	0.13 (0.07)	1.65 (0.20)	0.0014*	1.49 (0.17)	0.023*	1.38 (0.10)	0.0063*	
3	1	3	c.1346_1347insC; Thr449fsX	14	25.7 (13.6)	0.33 (0.2)	1.94 (0.24)	0.68	1.81 (0.12)	0.08	1.47 (0.08)	0.36	
4	1	2	c.1516+1G>C (splice defect)	15	23 (21.2)	0.55 (0.6)	1.79 (0.13)	0.25	1.55 (0.07)	0.21	1.40 (0.06)	0.10	
5	1	2	c.2729T>A (Val910Asp)	27	39.5 (26.2)	0.20 (0.0)	1.31 (0.33)	0.002*	1.46 (0.21)	0.15	1.23 (0.18)	0.03*	
6,7,8	3	6	c.2708-2711delTTAG; Val903fs	27	37.6 (18.0)	0.30 (0.4)	1.72 (0.34)	0.030*	1.57 (0.13)	0.14	1.34 (0.17)	0.014*	
9	1	3	c.2815delC (L939fs)	27	22.3 (18.6)	0.58 (0.4)	1.91 (0.31)	0.41	1.77 (0.16)	0.32	1.35 (0.01)	0.003*	
10	1	2	c.2797G>A (Val933Ile)	27	29 (14.1)	0.34 (0.4)	1.70 (0.07)	0.059	1.46 (0.06)	0.035*	1.44 (0.08)	0.29	
11	1	3	c.2819-2A>C splice defect	28	42.7 (18.7)	0.18 (0.2)	1.81 (0.15)	0.13	1.55 (0.25)	0.56	1.48 (0.08)	0.51	

BCVA = best-corrected visual acuity; SD = standard deviation.

*Statistically significant.

genic mutations listed in the <http://lbbma.univ-angers.fr/eOPA1/> database or have been recently reported.^{8,9} Two *OPA1* mutations are reported in this study for the first time: c.2815delC (exon 27: L939 frame shift) and c.2797G>A (exon 27: Val933Ile).

Table 3 and Figure 1 show the ONH parameters for DOA patients and control group. The comparison of DOA patients with controls showed a significantly smaller disc area ($P < 0.0001$), vertical disc diameter ($P = 0.018$), and horizontal disc diameter ($P < 0.0001$) in DOA patients.

However, after stratification of DOA patients by *OPA1* mutation (Table 2; Fig 2), we observed significant differences of all ONH parameters in only 1 mutation (c.984+3A>T) and in the disc area and in the vertical disc diameter in further 2 mutations (c.2729T>A and c.2708-2711delTTAG). Finally, we observed statistically significant differences in vertical and horizontal disc diameter in 2 other mutations (c.2797G>A and c.2815delC, respectively). The lack of significant differences for the other ONH parameters is most probably owing to the limited number of subjects available. Nevertheless, disc area and vertical disc diameters showed normal values in subjects with the c.1346_1347insC and the c.2815delC mutation, both predicted to induce a frame shift and a truncated protein product. In contradistinction, the only

2 previously reported cases with “DOA plus” phenotype associated with mitochondrial DNA multiple deletion and carrying a missense mutation (c.2729T>A)⁹ showed the smallest ONH size in our case series (Table 2; Fig 2). An example of 2 DOA patients with different size of the ONH is given in Figure 3.

Discussion

The main finding of the current study is that the *OPA1* mutant DOA patients, as a group, have an overall significantly smaller ONH as shown by the different parameters measured by OCT, compared with an age-matched control population. This observation suggests that *OPA1* influences ocular, and in particular, ONH development. The smaller ONH conformation in the *OPA1* mutant patients may, in turn, contribute to the pathogenic mechanism of DOA possibly explaining the early onset of the disease, which sometimes seems congenital.

OPA1 has a well-documented role in controlling apoptosis,^{13,16,17} which has been recently emphasized by modeling *OPA1* mutations in the ortholog gene of *Drosophila* (*dOPA1*).²⁶ The somatic expression of the homozygous *dOPA1* mutation in the *Drosophila* developing eyes caused rough (mispatterning) and glossy (decreased lens and pigment deposition) phenotype, possibly owing to altered control of apoptosis and increased production of reactive oxygen species.²⁶ Similarly, excessive reactive oxygen species production was also documented in *C elegans* carrying mutant *EAT-3* gene, the ortholog of human *OPA1* gene.²⁷ Thus, taking into account these recent results, *OPA1* mutations in humans may alter the ONH size by altering the pattern of developmental apoptosis during embryonic stages. In fact, the importance of *OPA1* in embryonic development is highlighted by the embryonic lethality observed in homozygous mutant animal models.^{28,29}

Table 3. Topographic Optic Nerve Head Measurements Comparison between Control Group and Dominant Optic Atrophy Patients

	Controls (n = 56 eyes), Mean (SD)	Dominant Optic Atrophy Patients (n = 28 eyes), Mean (DS)	P
Disc area (mm ²)	2.05 (0.33)	1.73 (0.26)	<0.0001*
Vertical disc diameter (mm)	1.67 (0.15)	1.58 (0.18)	0.018*
Horizontal disc diameter (mm)	1.55 (0.15)	1.38 (0.12)	<0.0001*

SD = standard deviation.

*Statistically significant.

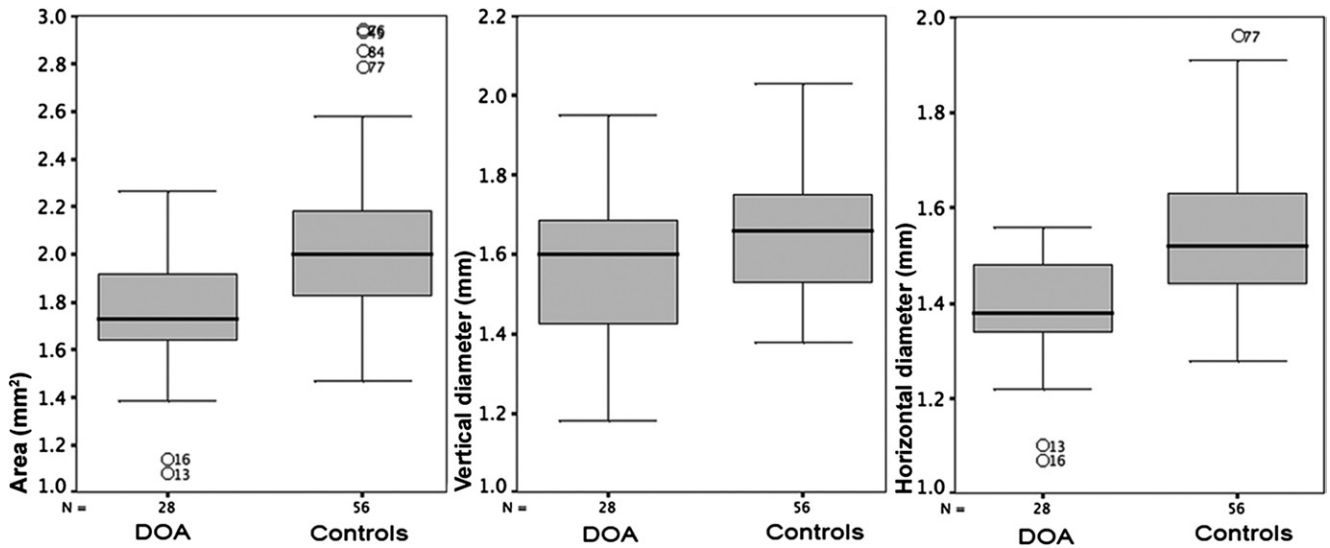


Figure 1. Disc area, vertical disc diameter and horizontal disc diameter in dominant optic atrophy (DOA) and controls. (Each box shows the median, quartiles, and extreme values; circles represent the outliers).

Stratifying the results of this study by *OPA1* mutation, we noticed a range of different degrees of ONH size. Subjects with the c.1346_1347insC or c.2815delC mutations were not distinguishable from normal subjects. However, those with the c.2729T>A mutation were on the lowest end of the range. Interestingly, the latter is a missense mutation associated with a “DOA plus” phenotype carrying mitochondrial DNA multiple deletions in the skeletal muscle as previously reported (family 2 in Zanna et al⁸). All the other mutations, including the common microdeletion c.2708-2711delTTAG, were associated with a variable reduction of ONH size. Overall, this subanalysis suggests a mutation dependent effect on ONH conformation.

A small ONH with a small cup-to-disc ratio characterized as “disc-at-risk” has been historically associated as a major predisposing factor for NAION.¹⁹ Recently, we reported that large ONH size may protect from developing LHON and improve the final visual outcome in affected subjects.²³ In both NAION and LHON, the pathology is a subacute/acute event; a small ONH, reflecting axonal crowding, may impose mechanical constraints. However, the current findings in DOA patients may suggest a different scenario. Optic neuropathy in DOA is a relentless, slowly progressive process that most likely invokes small-scale axonal degeneration, which does not implicate mechanical constraints. Thus, in contradistinction to NAION and

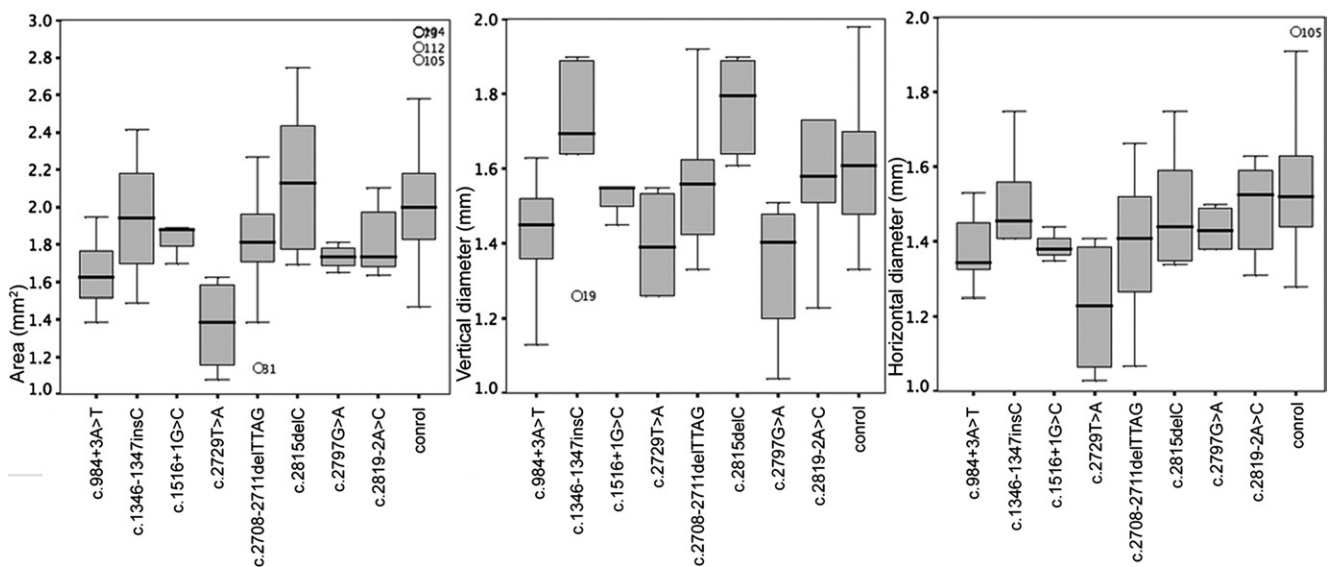


Figure 2. Disc area, vertical disc diameter, and horizontal disc diameter in the 8 different *OPA1* mutations, showed in Table 2, and controls. (Each box shows the median, quartiles, and extreme values; circles represent the outliers).

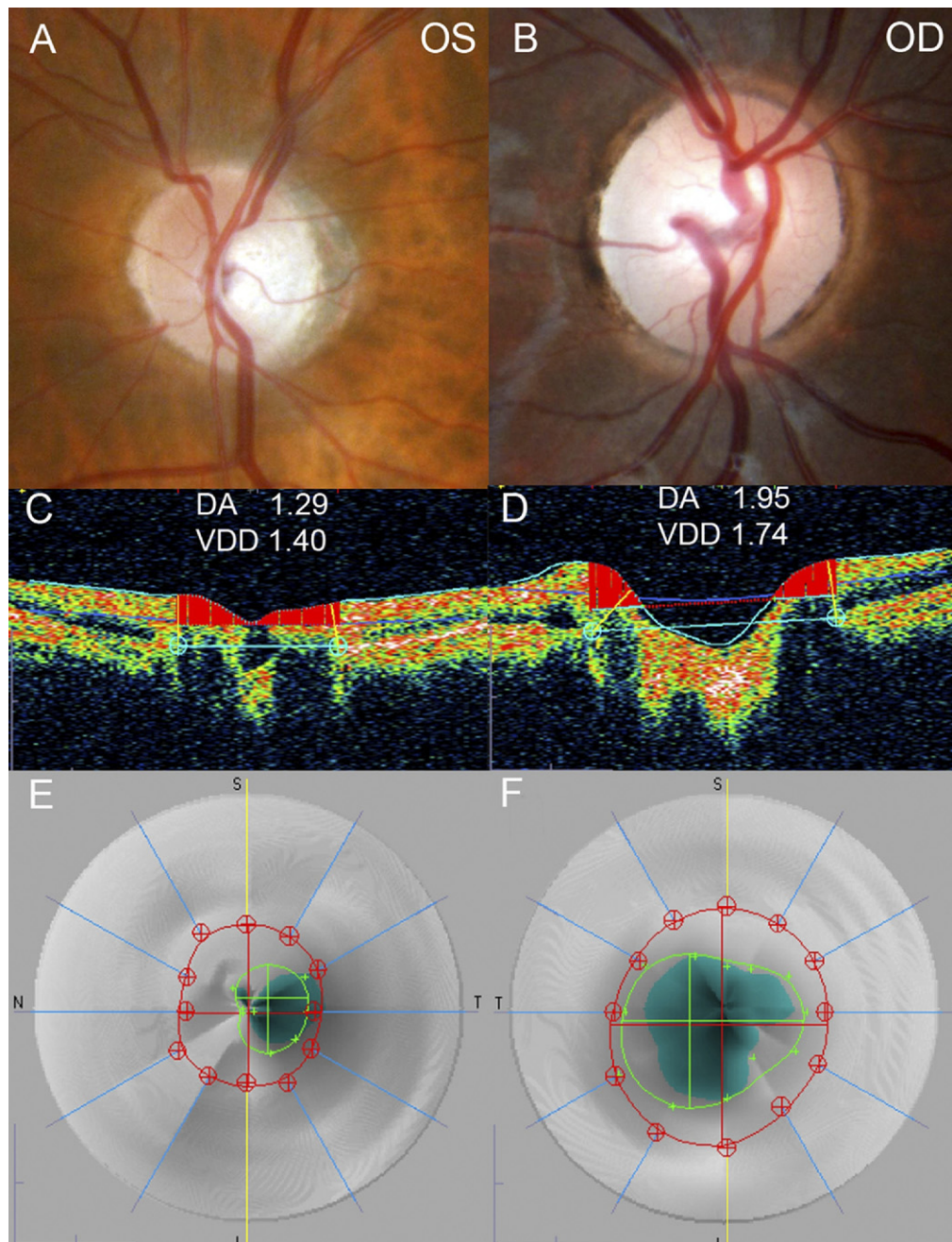


Figure 3. Representative optic nerve head color pictures and optical coherence tomography analysis of a dominant optic atrophy (DOA) patient with a small optic disc (A, C, E), and a DOA patient with normal optic disc size (B, D, F). DA = optic disc area; OD = right eye; OS = left eye; VDD = vertical disc diameter.

LHON, a critical issue is whether the small ONH in DOA is associated with an excessive crowding of axons or with a constitutive smaller number of axons. This last hypothesis is supported by the known role of OPA1 in controlling apoptosis and its importance in embryonic development as highlighted by the embryonic lethality of homozygous *OPA1* mutant mice.^{28,29} A recent study by OCT on a small number of DOA patients proposed a relative reduction of axonal numbers in the first decade of life, which may fit with a constitutive smaller number of axons at birth.³⁰

The role of OPA1 in apoptosis is thought to be independent of the control of mitochondrial fusion and relates to the involvement of OPA1 in the maintenance of cristae morphology, in particular keeping cristae junctions in a close conformation that sequester cytochrome *c* (*cyt c*).^{13,16,17} OPA1 haploinsufficiency or dysfunction as with missense mutations may alter this *cyt c* compartmentalization, increasing the cells' predisposition to undergo apoptosis. Genes implicated in regulating apoptosis during embryogenesis, as now proposed for *OPA1*, are critical in eye

development. Multiple examples of how altered function of such genes interferes with eye development come from mouse models. For example the *Bax*^{-/-} mouse present a >50% increase in retinal ganglion cell numbers, whereas the opposite occurs with the *Bcl2*^{-/-} mouse model, which is associated with the loss of one third of retinal ganglion cells.³¹ Further genes with a pivotal role in eye development are homeobox genes such as *Vax1* and *Vax2*, or the highly conserved transcription factors *Pax6* and *Pax2*.^{32,33} Genetic variation in all these genes, including *OPA1*, may give rise to the observed variability in ONH anatomic conformation in the general population. Furthermore, genetic variation in the *OPA1* gene may become relevant as modifier in those ocular diseases for which ONH size has been implicated such as the already mentioned NAION and LHON.^{19,23} Moreover, an association of *OPA1* polymorphisms with the risk to develop normal tension glaucoma has been proposed, even if these initial studies have not been replicated in other series.³⁴⁻³⁷

Optic nerve hypoplasia could be also modulated by genetic variability in the *OPA1* gene. Optic nerve hypoplasia is a poorly understood condition, sometimes difficult to unequivocally diagnose; in about 20% of cases, it is an isolated feature, without correlated central nervous system developmental abnormalities.³⁸ Our study on DOA patients poses the question of a possible problem with differential diagnosis of some DOA cases with optic nerve hypoplasia. We herein propose that variants in the *OPA1* gene may underlay some cases of optic nerve hypoplasia and *OPA1* sequence analysis is warranted to solve this hypothesis.

In conclusion, our study proposes a previously unrecognized role for *OPA1* in eye development, and in particular in modeling the ONH size and conformation. A proper investigation of axonal numbers in ONH of DOA patients is warranted to clarify the issue of axonal crowding. Our study has broad implications both for DOA pathogenesis and for a modifying role of *OPA1* in other eye pathologies. A strict genotype/phenotype correlation of our findings at the single mutation level requires an investigation in a larger series of DOA patients. Ultimately, ONH size may have implications for the phenotypic expression of optic neuropathy in DOA in terms of age of onset, disease progression, severity, and penetrance.

References

- Kjer P. Infantile optic atrophy with dominant mode of inheritance: a clinical and genetic study of 19 Danish families. *Acta Ophthalmol Suppl* 1959;164(suppl):1-147.
- Newman NJ. Hereditary optic neuropathies. In: Miller NR, Newman NJ, eds; Bioussé V, Kerrison JB, assoc eds. *Walsh and Hoyt's Clinical Neuro-Ophthalmology*. 6th ed. Vol 1. Philadelphia: Lippincott Williams & Wilkins; 2005:465-501.
- Votruba M, Moore AT, Bhattacharya SS. Clinical features, molecular genetics, and pathophysiology of dominant optic atrophy. *J Med Genet* 1998;35:793-800.
- Carelli V, Ross-Cisneros FN, Sadun AA. Mitochondrial dysfunction as a cause of optic neuropathies. *Prog Ret Eye Res* 2004;23:53-89.
- Alexander C, Votruba M, Pesch UE, et al. *OPA1*, encoding a dynamin-related GTPase, is mutated in autosomal dominant optic atrophy linked to chromosome 3q28. *Nat Genet* 2000;26:211-5.
- Delettre C, Lenaers G, Griffioen JM, et al. Nuclear gene *OPA1*, encoding a mitochondrial dynamin-related protein, is mutated in dominant optic atrophy. *Nat Genet* 2000;26:207-10.
- Ferré M, Amati-Bonneau P, Tourmen Y, et al. *eOPA1*: an online database for *OPA1* mutations. *Hum Mutat* 2005;25:423-8.
- Zanna C, Ghelli A, Porcelli AM, et al. *OPA1* mutations associated with dominant optic atrophy impair oxidative phosphorylation and mitochondrial fusion. *Brain* 2008;131:352-67.
- Amati-Bonneau P, Valentino ML, Reynier P, et al. *OPA1* mutations induce mitochondrial DNA instability and optic atrophy 'plus' phenotypes. *Brain* 2008;131:338-51.
- Hudson G, Amati-Bonneau P, Blakely EL, et al. Mutation of *OPA1* causes dominant optic atrophy with external ophthalmoplegia, ataxia, deafness and multiple mitochondrial DNA deletions: a novel disorder of mtDNA maintenance. *Brain* 2008;131:329-37.
- Cohn AC, Toomes C, Potter C, et al. Autosomal dominant optic atrophy: penetrance and expressivity in patients with *OPA1* mutations. *Am J Ophthalmol* 2007;143:656-62.
- Olichon A, Guillou E, Delettre C, et al. Mitochondrial dynamics and disease, *OPA1*. *Biochim Biophys Acta* 2006;1763:500-9.
- Olichon A, Baricault L, Gas N, et al. Loss of *OPA1* perturbs the mitochondrial inner membrane structure and integrity, leading to cytochrome c release and apoptosis. *J Biol Chem* 2003;278:7743-6.
- Lodi R, Tonon C, Valentino ML, et al. Deficit of in vivo mitochondrial ATP production in *OPA1*-related dominant optic atrophy. *Ann Neurol* 2004;56:719-23.
- Amati-Bonneau P, Guichet A, Olichon A, et al. *OPA1* R445H mutation in optic atrophy associated with sensorineural deafness. *Ann Neurol* 2005;58:958-63.
- Frezza C, Cipolat S, Martins de Brito O, et al. *OPA1* controls apoptotic cristae remodeling independently from mitochondrial fusion. *Cell* 2006;126:177-89.
- Cipolat S, Rudka T, Hartmann D, et al. Mitochondrial rhomboid *PARL* regulates cytochrome c release during apoptosis via *OPA1*-dependent cristae remodeling. *Cell* 2006;126:163-75.
- Hoffmann EM, Zangwill LM, Crowston JG, Weinreb RN. Optic disk size and glaucoma. *Surv Ophthalmol* 2007;52:32-49.
- Jonas JB, Xu L. Optic disc morphology in eyes after nonarteritic anterior ischemic optic neuropathy. *Invest Ophthalmol Vis Sci* 1993;34:2260-5.
- Mullie MA, Sanders MD. Scleral canal size and optic nerve head drusen. *Am J Ophthalmol* 1985;99:356-9.
- Girkin CA, McGwin G Jr, McNeal SF, DeLeon-Ortega J. Racial differences in the association between optic disc topography and early glaucoma. *Invest Ophthalmol Vis Sci* 2003;44:3382-7.
- Healey PR, Mitchell P. Optic disk size in open-angle glaucoma: the Blue Mountains Eye Study. *Am J Ophthalmol* 1999;128:515-7.
- Ramos CV, Bellusci C, Savini G, et al. Association of optic disc size with development and prognosis of Leber's hereditary optic neuropathy. *Invest Ophthalmol Vis Sci* 2009;50:1666-74.
- Pesch UE, Leo-Kottler B, Mayer S, et al. *OPA1* mutations in patients with autosomal dominant optic atrophy and evidence for semi-dominant inheritance. *Hum Mol Genet* 2001;10:1359-68.
- Schimpf S, Schaich S, Wissinger B. Activation of cryptic splice sites is a frequent splicing defect mechanism caused by

- mutations in exon and intron sequences of the OPA1 gene. *Hum Genet* 2006;118:767–71.
26. Yarosh W, Monserrate J, Tong JJ, et al. The molecular mechanisms of OPA1-mediated optic atrophy in *Drosophila* model and prospects for antioxidant treatment [report online]. *PLoS Genet* 2008;4:e6. Available at: <http://www.plosgenetics.org/article/info%3Adoi%2F10.1371%2Fjournal.pgen.0040006>. Accessed November 18, 2009.
 27. Kanazawa T, Zappaterra MD, Hasegawa A, et al. The *C. elegans* Opa1 homologue EAT-3 is essential for resistance to free radicals [report online]. *PLoS Genet* 2008;4:e1000022. Available at: <http://www.plosgenetics.org/article/info%3Adoi%2F10.1371%2Fjournal.pgen.1000022>. Accessed November 18, 2009.
 28. Alavi MV, Bette S, Schimpf S, et al. A splice site mutation in the murine Opa1 gene features pathology of autosomal dominant optic atrophy. *Brain* 2007;130:1029–42.
 29. Davies VJ, Hollins AJ, Piechota MJ, et al. Opa1 deficiency in a mouse model of autosomal dominant optic atrophy impairs mitochondrial morphology, optic nerve structure and visual function. *Hum Mol Genet* 2007;16:1307–18.
 30. Milea D, Sander B, Wegener M, et al. Axonal loss occurs early in dominant optic atrophy. *Acta Ophthalmol* 2010;88:342–6.
 31. Cellierino A, Bahr M, Isenmann S. Apoptosis in the developing visual system. *Cell Tissue Res* 2000;301:53–69.
 32. Ohsaki K, Morimitsu T, Ishida Y, et al. Expression of the Vax family homeobox genes suggests multiple roles in eye development. *Genes Cells* 1999;4:267–76.
 33. Kozmik Z. Pax genes in eye development and evolution. *Curr Opin Genet Dev* 2005;15:430–8.
 34. Aung T, Ocaka L, Ebenezer ND, et al. A major marker for normal tension glaucoma: association with polymorphisms in the OPA1 gene. *Hum Genet* 2002;110:52–6.
 35. Aung T, Ocaka L, Ebenezer ND, et al. Investigating the association between OPA1 polymorphisms and glaucoma: comparison between normal tension and high tension primary open angle glaucoma. *Hum Genet* 2002;110:513–4.
 36. Liu Y, Schmidt S, Qin X, et al. No association between OPA1 polymorphisms and primary open-angle glaucoma in three different populations. *Mol Vis* [serial online] 2007;13:2137–41. Available at: <http://www.molvis.org/molvis/v13/a242/>. Accessed November 18, 2009.
 37. Yu-Wai-Man P, Stewart JD, Hudson G, et al. OPA1 increases the risk of normal but not high tension glaucoma. *J Med Genet* 2010;47:120–5.
 38. Borchert M, Garcia-Filion P. The syndrome of optic nerve hypoplasia. *Curr Neurol Neurosci Rep* 2008;8:395–403.

Footnotes and Financial Disclosures

Originally received: August 14, 2009.

Final revision: December 28, 2009.

Accepted: December 29, 2009.

Available online: April 24, 2010.

Manuscript no. 2009-1102.

¹ Studio Oculistico d'Azeglio, Bologna, Italy.

² Dipartimento di Scienze Neurologiche, Università di Bologna, Bologna, Italy.

³ Fondazione G.B. Bietti-IRCCS, Roma, Italy.

⁴ Sezione di Oftalmologia, Università di Parma, Parma, Italy.

⁵ Azienda San Camillo-Forlanini, Rome, Italy.

⁶ Ospedale San Giovanni, Tivoli, Italy.

⁷ Unit of Molecular Neurogenetics, Pierfranco and Luisa Mariani Center for the Study of Children's Mitochondrial Disorders, Foundation "C. Besta" Neurological Institute-IRCCS, Milan, Italy.

⁸ Doheny Eye Institute, Keck University of Southern California, Los Angeles, California.

⁹ Molecular Genetics Laboratory, Institute for Ophthalmic Research, Centre for Ophthalmology, University Clinics Tuebingen, Tuebingen, Germany.

Presented in part at: Association for Research in Vision and Ophthalmology Meeting, May 2007, Fort Lauderdale, Florida.

Financial Disclosure(s):

The authors have no proprietary or commercial interest in any of the materials discussed in this article.

Supported by a Telethon Italy grant (#GGP06233 to VC) and Italian Ministry of health grant (RF-FGB-2006-368547).

Correspondence:

Piero Barboni, MD, Studio Oculistico d'Azeglio, Via d'Azeglio 5, 40123 Bologna, Italy. E-mail: p.barboni@studiodazeglio.it.